

Birt-Hogg-Dubé Syndrome: A Rare Cause of Pulmonary Cysts

Carolina A. Souza¹
Richard Finley²
Nestor L. Müller¹

Birt-Hogg-Dubé syndrome is a rare autosomal-dominant inherited disorder characterized by the presence of firm facial papules that on biopsy are shown to represent fibrofolliculomas [1–3]. Patients with Birt-Hogg-Dubé syndrome have a high predisposition to malignant renal tumors, which are often bilateral and multifocal [2–4]. Several studies have shown that the prevalence of bullous emphysema, thin-walled cysts, and spontaneous pneumothorax is increased in these patients [2, 3, 5]. The description of the pulmonary complications has been limited to radiographs and published in the dermatologic literature [2, 3, 5].

We report the radiographic and high-resolution CT findings in a 54-year-old woman with Birt-Hogg-Dubé syndrome and history of renal cell carcinoma. The pulmonary abnormalities consisted of multiple thin-walled cysts measuring 1–5.5 cm in diameter and involving mainly the lower lobes.

Case Report

A 54-year-old woman presented with an episode of sudden onset of chest pain during air travel. Chest radiography showed multiple focal radiolucent areas along the left heart border and at the right costophrenic angle. There was no pneumothorax. High-resolution CT of the chest, performed on an 8-MDCT scanner using a 1.3-mm collimation and a high-resolution (bone) reconstruction algorithm confirmed the presence of multiple pulmonary cysts, most numerous at the lung bases. The pulmonary cysts were sharply marginated air-containing lesions with walls 2 mm or less thick and measuring 1–5.5 cm in diameter [6]. The largest one was seen adjacent to the pericardium in the right lower lobe, measuring 5.5 × 5.4 cm in diameter (Fig. 1). Several cysts measuring 1–5 cm in diameter were present in the lingula and left lower lobe. Only a few cysts measuring

1–1.5 cm in diameter were seen in the upper lobes (Fig. 1). No other abnormality was seen.

The air-containing lesions were classified as cysts instead of bullae because, by definition, bullae are associated with emphysema and typically involve mainly the peripheral regions of the upper lobes [6]. The patient had only 1 pack-year smoking history and had stopped smoking cigarettes 34 years before the current presentation. The lung parenchyma between the cysts appeared normal on CT, and her pulmonary function test results including static lung volumes, expiratory flows, and carbon monoxide diffusing capacity were normal.

The patient had a 5-year history of multiple skin papules, which on skin biopsy were shown to be fibrofolliculomas. She had undergone right radical nephrectomy for renal cell carcinoma 27 years previously. Her family medical history revealed several relatives with a clinical diagnosis of Birt-Hogg-Dubé syndrome. Two of the relatives had previous kidney tumors.

Physical examination performed by a dermatologist showed typical cutaneous manifestations of Birt-Hogg-Dubé syndrome, including almost 100 small papules distributed in her face, neck, and trunk. Biopsy of a retroauricular papule showed perifollicular fibrosis, consistent with histologic diagnosis of fibrofolliculoma. Follow-up sonography examinations of the native kidney have not shown additional renal lesions, and no evidence of recurrence has been visualized in the renal bed on the right side.

Discussion

In 1977, Birt, Hogg, and Dubé reported a kindred study of 70 members of three generations, 15 of whom exhibited multiple small skin-colored to grayish-white dome-shaped papules distributed over the face, neck, and upper trunk. Histologic analysis revealed fi-

DOI:10.2214/AJR.04.1475

Received September 17, 2004; accepted after revision November 12, 2004.

¹Department of Radiology, Vancouver General Hospital and University of British Columbia, 899 W 12th Ave., Vancouver, BC, V5Z 1M9 Canada. Address correspondence to N. L. Müller.

²Department of Surgery, Vancouver General Hospital and University of British Columbia, Vancouver, BC, V5Z 1M9 Canada.

AJR 2005;185:1237–1239

0361–803X/05/1855–1237

© American Roentgen Ray Society

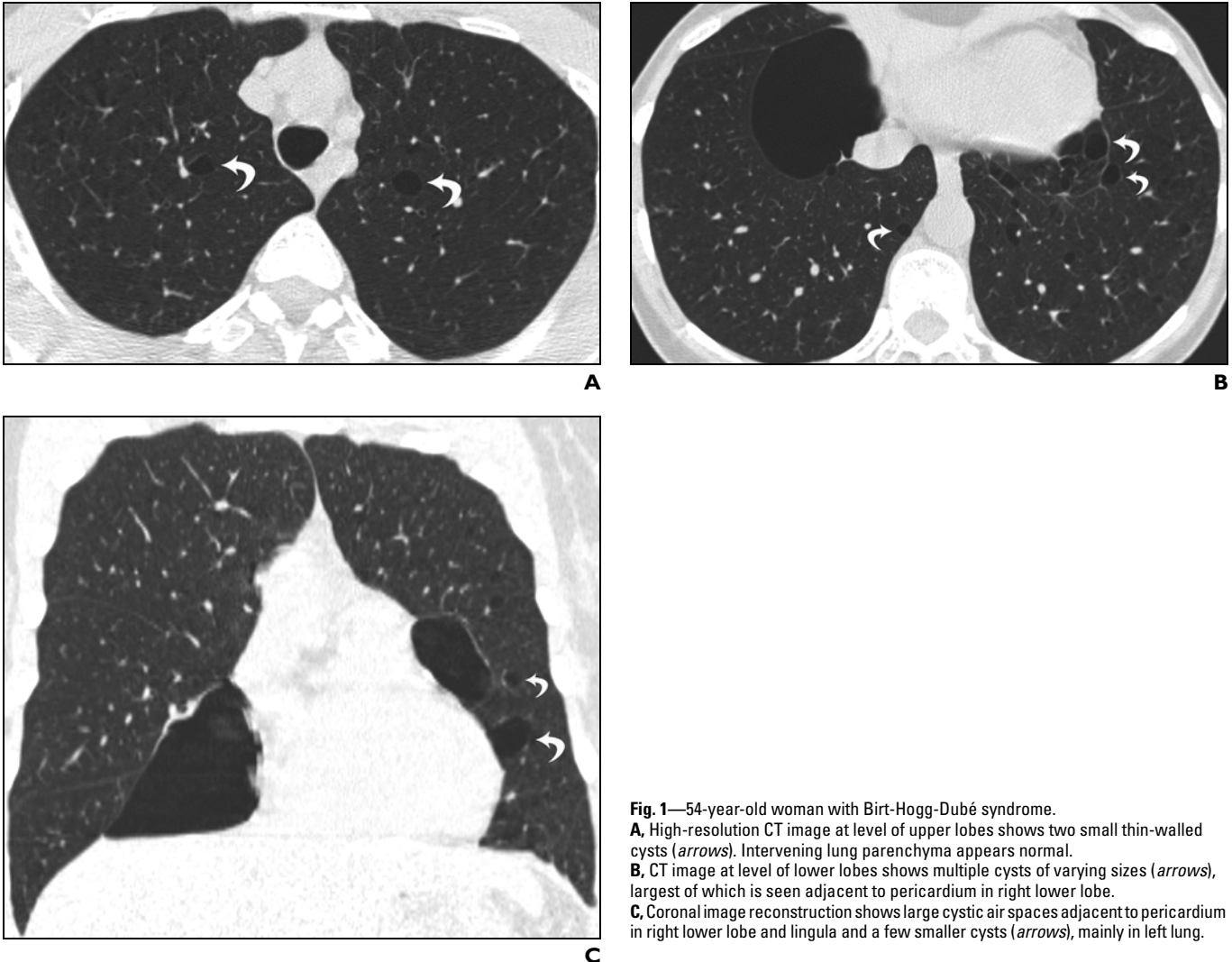


Fig. 1—54-year-old woman with Birt-Hogg-Dubé syndrome.
A, High-resolution CT image at level of upper lobes shows two small thin-walled cysts (arrows). Intervening lung parenchyma appears normal.
B, CT image at level of lower lobes shows multiple cysts of varying sizes (arrows), largest of which is seen adjacent to pericardium in right lower lobe.
C, Coronal image reconstruction shows large cystic air spaces adjacent to pericardium in right lower lobe and lingula and a few smaller cysts (arrows), mainly in left lung.

brofolliculomas, trichodiscomas, and acrochordons [1]. The triad of lesions, inherited as an autosomal-dominant trait, was named “Birt-Hogg-Dubé syndrome.” Several studies since then have shown that all these patients have skin fibrofolliculomas but that trichodiscomas and acrochordons are less common [2–5].

Recently, the gene mutation responsible for the development of the disease was identified. The gene locus is localized within chromosome 17p11.2, in an unstable genomic region that is associated with a number of diseases [2, 7]. Papules, varying in number from a few to several hundred, with a histological diagnosis of fibrofolliculoma, are the hallmark of the syndrome [1, 2]. They are asymptomatic and develop during the third or fourth decades of life, increasing in number and size as patients grow older.

Patients with Birt-Hogg-Dubé syndrome are at increased risk for developing different types of renal tumors [2–4, 8, 9], ranging from benign oncocytomas to malignant renal carcinomas. Familial kidney tumors are often bilateral and multifocal and are usually asymptomatic in the initial stages. It is therefore recommended that affected patients and family members undergo abdominal CT and renal sonography screening for renal cancer [3, 4, 8, 9]. Other systemic conditions associated with Birt-Hogg-Dubé syndrome include colonic polyposis and ophthalmologic disorders, such as progressive flecked chorioretinopathy and chorioretinal scars [7].

The presence of lung cysts in association with Birt-Hogg-Dubé syndrome was first described by Toro et al. [3] in 1999 in a study of 152 individuals from 49 families with famil-

ial renal neoplasms syndromes. Among these patients, three of the 13 who had Birt-Hogg-Dubé syndrome exhibited pulmonary cysts, and one of these three patients developed pneumothorax [3]. A few additional cases of lung cysts and spontaneous pneumothorax have since been reported in the literature [2, 5, 7–9]. Bullous emphysema has also been described [2, 7]. The increased frequency of reports on pulmonary cystic abnormalities in these patients strongly suggests that they are manifestations of Birt-Hogg-Dubé syndrome rather than chance associations.

The incidence of Birt-Hogg-Dubé syndrome is unknown. Prognosis depends on associated comorbid factors, particularly renal cell carcinoma, because the typical dermatologic lesions are benign, causing only cosmetic concerns. Given its autosomal-dominant trait, genetic counseling is advised.

Birt-Hogg-Dubé Syndrome: A Rare Cause of Pulmonary Cysts

Birt-Hogg-Dubé syndrome needs to be distinguished from more common conditions associated with multiple pulmonary cysts such as lymphangioliomyomatosis, Langerhans cell histiocytosis, lymphocytic interstitial pneumonitis, and *Pneumocystis carinii* pneumonia. The distribution and the large size of some of the cysts seen in the current case allow ready distinction from lymphangioliomyomatosis, which is characterized by the presence of thin-walled, typically round, cysts in a diffuse distribution throughout the lungs. The findings are also distinct from those of Langerhans cell histiocytosis, which typically presents with cysts and nodules and spares the lung bases. The absence of other parenchymal abnormalities such as ground-glass attenuation and small nodules and the lack of clinical history of an underlying immunologic process, such as Sjögren's syndrome, rule out the possibility of lymphocytic interstitial pneumonitis, and clinical history rules out previous *P. carinii* pneumonia.

In summary, we describe a case of Birt-Hogg-Dubé syndrome associated with thin-walled pulmonary cysts, an association not previously reported in the radiologic literature. Radiologists, as well clinicians, must be able to recognize this syndrome and be aware of its associated findings and potential complications.

References

1. Birt AR, Hogg GR, Dubé WJ. Hereditary multiple fibrofolliculomas with trichodiscomas and acrochordons. *Arch Dermatol* 1977; 113:1674-1677
2. Schmidt LS, Warren MB, Nickerson ML, et al. Birt-Hogg-Dubé syndrome, a genodermatosis associated with spontaneous pneumothorax and kidney neoplasia, maps to chromosome 17p11.2. *Am J Hum Genet* 2001; 69:876-882
3. Toro JR, Glenn G, Duray P, et al. Birt-Hogg-Dubé syndrome: a novel marker of kidney neoplasia. *Arch Dermatol* 1999; 135:1195-1202
4. Choyke PL, Glenn GM, Walther MM, Zbar B, Linehan WM. Hereditary renal cancers. *Radiology* 2003; 226:33-46
5. Kupres KA, Krivda SJ, Turiansky GW. Numerous asymptomatic facial papules and multiple pulmonary cysts: a case of Birt-Hogg-Dubé syndrome. *Cutis* 2003; 72:127-131
6. Webb WR, Müller NL, Naidich DP. Standardized terms of high-resolution computed tomography of the lung: a proposed glossary. *J Thorac Imaging* 1993; 8:167-185
7. Zbar B, Alvord WG, Glenn G, et al. Risk of renal and colonic neoplasms and spontaneous pneumothorax in the Birt-Hogg-Dubé syndrome. *Cancer Epidemiol Biomarkers Prev* 2002; 11:393-400
8. Roth JS, Rabinowitz AD, Benson M, Grossman ME. Bilateral renal cell carcinoma in the Birt-Hogg-Dubé syndrome. *J Am Acad Dermatol* 1993; 29:1055-1056
9. Lindor NM, Hand J, Burch PA, Gibson LE. Birt-Hogg-Dubé syndrome: an autosomal dominant disorder with predisposition to cancers of the kidney, fibrofolliculomas, and focal cutaneous mucinosis. *Int J Dermatol* 2001; 40:653-656