

Review

Open Access

## Chromophobe renal cell cancer - review of the literature and potential methods of treating metastatic disease

Rafał Stec\*<sup>1</sup>, Bartłomiej Grala<sup>2</sup>, Michał Mączewski<sup>3</sup>, Lubomir Bodnar<sup>1</sup> and Cezary Szczylik<sup>1</sup>

Address: <sup>1</sup>Department of Oncology, Military Institute of Health Services, Warsaw, Poland, <sup>2</sup>Department of Pathology, Military Institute of Health Services, Warsaw, Poland and <sup>3</sup>Department of Clinical Physiology, Medical Center of Postgraduate Education, Warsaw, Poland

Email: Rafał Stec\* - [drorafals@wp.pl](mailto:drorafals@wp.pl); Bartłomiej Grala - [gralab@wp.pl](mailto:gralab@wp.pl); Michał Mączewski - [maczmich@cmkp.edu.pl](mailto:maczmich@cmkp.edu.pl); Lubomir Bodnar - [lubo@esculap.pl](mailto:lubo@esculap.pl); Cezary Szczylik - [cszczylik@wp.pl](mailto:cszczylik@wp.pl)

\* Corresponding author

Published: 7 October 2009

Received: 1 August 2009

*Journal of Experimental & Clinical Cancer Research* 2009, **28**:134 doi:10.1186/1756-9966-28-134

Accepted: 7 October 2009

This article is available from: <http://www.jeccr.com/content/28/1/134>

© 2009 Stec et al; licensee BioMed Central Ltd.

This is an Open Access article distributed under the terms of the Creative Commons Attribution License (<http://creativecommons.org/licenses/by/2.0>), which permits unrestricted use, distribution, and reproduction in any medium, provided the original work is properly cited.

### Abstract

Chromophobe renal cell carcinoma (ChRCC) is a subtype of renal cell carcinoma (RCC). ChRCC is diagnosed mainly in 6th decade of life. An incidence of ChRCC is similar in both men and woman. Eighty six percent of ChRCCs cases are diagnosed in stage I or 2. Prognosis of ChRCC is better than in other types of RCC. Five- and 10-year disease free survival (DFS) for ChRCC was 83.9% and 77.9%, respectively. Expression of immunohistological markers: cytokeratins (CK), vimentin, epithelial membrane antigen (EMA), CD10 could be potentially helpful in diagnosis of different subtypes of RCC. From all conventional RCC, CD 117 was detected (overexpression) in membrane of cells ChRCC.

Overexpression of CD 117 on cellular membranes of ChRCC could be a potential target for kinase inhibitors like: imatinib, dasatinib, nilotinib. The potential targets for other kinase inhibitors (sunitinib and sorafenib) in ChRCC seem to be VEGFR and PDGFR. On the basis for formulating research hypotheses which should be verified by prospective studies.

### Epidemiology

Renal cell carcinoma (RCC) is rather a rare neoplasm (in Poland about 3% of all tumors). According to the most recent National Cancer Register in Poland, 2150 men and 1501 women were diagnosed with renal cancer in 2004 [1].

Approximately 200,000 new cases of RCC are diagnosed annually worldwide, while the number of deaths caused by RCC approaches 100,000. Cure can be obtained in 70-90% of patients in the TNM stage I, in 55-70% of patients in stage II, in 20-30% of patients in stage III, and in less than 10% in stage IV [2].

The 2004 World Health Organization (WHO) classification of RCC recognized several subtypes of RCC. Most common subtypes are: clear cell RCC (70%), papillary RCC (10-15%), chromophobe RCC (4-6%), collecting duct carcinoma (about 1%) and unclassified RCC (4-5%) [3,4].

Chromophobe RCC (ChRCC) is diagnosed mainly in 6th decade of life. An incidence of ChRCC is similar in both men and woman [5]. 86% of ChRCCs are diagnosed in stage 1 or 2 [3]. Renal vein invasion is seen in about 5% of cases [5].

Incidence of metastatic disease in chromophobe renal cell carcinoma is 6-7% [6,7].

In summary of 28 cases based on 7 reports, most common metastatic sites were liver (39%) and lung (36%) [6].

### Pathology

Chromophobe RCC was first described in patients by Thoenes in 1985 [8].

Macroscopically, ChRCC is a solitary, circumscribed, and not capsulated mass with a homogeneous light brown cut surface. The median tumor size of ChRCC is 6.0 cm, and it is larger than that of other subtypes [7].

Microscopically, it contains of large, polygonal cells with prominent cell membrane [5]. Cytoplasm is pale and resistant to staining with hematoxylin and eosin. ChRCC cells have irregular nuclei with perinuclear clear halo. The tumor blood vessels have thick walls and are eccentrically hyalinized [3].

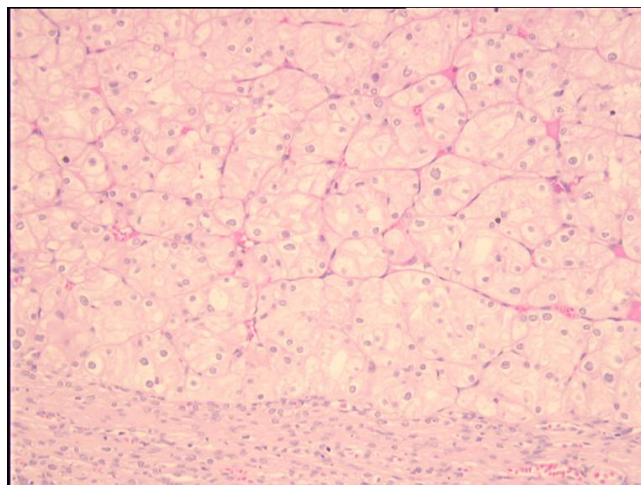
Chromophobe RCC is a heterogeneous group including classic type, eosinophilic type and mixed type. Eosinophilic variant (containing greater than 80% eosinophilic cells) has areas similar to renal oncocytomas (nested, alveolar or sheetlike architecture with eosinophilic granularity, perinuclear clearing, peripheral accentuation of cytoplasm) and it is often bilateral (11%) and multifocal (22%). Classic type of chromophobe RCC (containing greater than 80% pale cells) is associated with necrosis or sarcomatoid change. It has alveolar or sheet-like architecture and cytoplasm with flocculent "soap-bubble" appearance. Chromophobe RCCs with mixed histology have variable architecture (containing admixture of pale and eosinophilic cells) [6].

Microscopic tumor necrosis and sarcomatoid change are known to be aggressive with a high potential for distant metastases [6].

One of the diagnostic criteria of ChRCC is Hale colloidal iron [5], another are intracytoplasmic microvesicles between 250-400 nm in diameter [9] (Figure 1- Chromophobe renal cell carcinoma, HE, 200×; Figure 2 - Positive reaction showing the presence of colloidal iron in cytoplasm of ChRCC, 400×).

They can be demonstrated by electron microscopy, which is not used routinely in diagnosis of chromophobe RCC.

The main diagnostic criteria of chromophobe RCC is morphology coupled with characteristic immunophenotype (diffuse CK7, and KIT positivity).

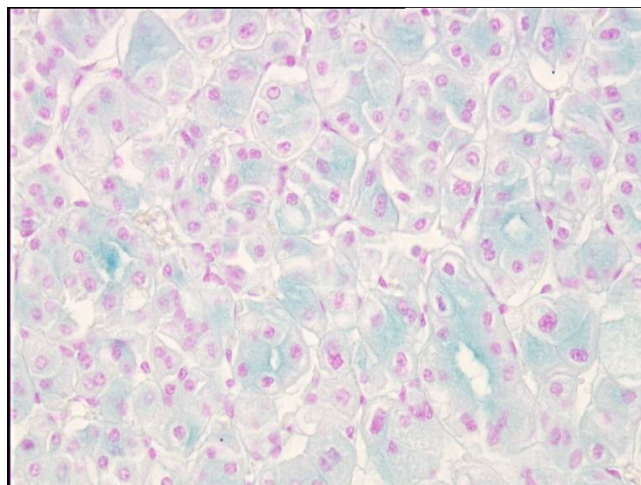


**Figure 1**  
**Chromophobe renal cell carcinoma, HE, 200×.**

Variable expression patterns of cytokeratins (CK), vimentin, epithelial membrane antigen (EMA), CD10 and parvalbumin can be potentially helpful in diagnosis of different subtypes of RCC. Vimentin was reported positive in 0-21% of ChRCC, CD10 in 0-33% of ChRCC, CK7 in 60-100% of ChRCC, CK8 in 50% of ChRCC, CK18 in 100% of ChRCC, CK19 in 33% of ChRCC, CK20 in 12.5% of ChRCC, EMA 75-100% of ChRCC and parvalbumin 100% of ChRCC. Sometimes ChRCC can be mistaken for renal oncocytoma [10,11] (Table 1).

### Clinical and Histomorphological Features

Prognosis in ChRCC is better than in other types of RCC. Five- and 10-year DFS for chromophobe RCC was 83.9%



**Figure 2**  
**Positive reaction showing the presence of colloidal iron in cytoplasm of ChRCC, 400×.**

**Table 1: Expression of immunohistological markers of ChRCC**

Immunohistological markers of ChRCC	CK 7	CK 8	CK 18	CK 19	CK 20	Vimentin	EMA	CD10	Parvalbumin
Positive reactivity (%)	60-100	50	100	33	12.5	0-21	75-100	0-33	100

and 77.9%, respectively [12]. The median time from nephrectomy to metastasis detection, and from metastasis detection to death were twice as long for ChRCC than for other subtypes of RCC (papillary, clear cell RCC) [7].

In univariate analysis: sarcomatoid change ( $p < 0.001$ ), microscopic necrosis ( $p = 0.019$ ), tumor size ( $p = 0.025$ ), pT stage (3.4 vs. 1.2;  $p < 0.001$ ), broad alveolar growth ( $p = 0.012$ ), vascular invasion ( $p = 0.020$ ), and Fuhrman nuclear grade (grade 4 vs.3 vs 2;  $p < 0.001$ ) were associated with aggressive ChRCC behavior. Independent predictors (Multivariable Cox Regression) of aggressive ChRCC included: pT stage (pT 3.4 vs. pT 1.2;  $p = 0.025$ , relative hazard 3.4), sarcomatoid change ( $p = 0.013$ , relative hazard 4.7) and microscopic necrosis ( $p = 0.020$ , relative hazard 3.5) [6]. Other factors like: age, sex, histologic subtyping by clear, eosinophilic or mixed cell types, tubulocystic pattern, degenerate or symplastic atypia were not predictors of chromophobe RCC behavior.

The patients with aggressive phenotype of chromophobe RCC may be candidates for adjuvant therapies as they become available [6].

ChRCCs are hyperechogenic in ultrasound examination, CT imaging or MRI demonstrate homogeneous enhancement. A spoke-wheel pattern of contrast enhancement is characteristic for ChRCC and for oncocytoma [13]. Most of ChRCCs are sporadic, but sometimes they are associated with BHD (Birt-Hogg-Dubè) syndrome [14].

**Genetic Syndrome associated with chromophobe RCC**

BHD syndrome is an autosomal dominant disorder that includes: benign skin tumor (skin tags, fibrofolliculomas), renal epithelial neoplasms (ChRCC, oncocytoma) and spontaneous pneumothorax. Renal tumors are often multifocal and bilateral. BHD gene encodes potential tumor suppressor protein - folliculin on 17p11 [15].

ChRCCs is characterized by length polymorphism such as loss of chromosomal material involving chromosomes: 1, 2, 3p, 6, 10, 13, 17p, 17q and 21 [16,17]. It may be helpful in distinguishing between clear, papillary and chromophobe subtypes of RCC.

**Expression of CD117 (KIT)**

KIT (CD117) is a type III receptor tyrosine kinase that plays a role in intracellular signal transduction in several

cell types. It regulates apoptosis, cell differentiation, proliferation, chemotaxis, and adhesion. Pathologic activation of KIT through gain-of-function mutations leads to neoplasia of KIT-dependent and KIT-positive cell types in different systems: Cajal cells - gastrointestinal stromal tumors (GISTs), myeloid cells - myeloid leukemia. In addition, many tumors have positive KIT immunoreactivity: small cells carcinomas, adenoid cystic carcinoma, chromophobe, thymic and sometimes ovarian and breast carcinomas [18].

In normal tissue of kidney KIT showed weak immunoreactivity only in the cytoplasm of distal tubules [19]. From all RCCs, KIT gene product was detected (overexpression) in membrane of cells ChRCC (88-100%) [19,20]. This is in agreement with histogenetic origin of chromophobe RCC from distal tubules.

KIT expression in classic variant is more often than eosinophilic variant (82% vs. 67%) [21].

Thus, immunohistochemical detection of KIT expression appears to be useful in diagnosis and treatment of ChRCC.

Yamazaki et al. reported upregulation of *c-kit* gene expression in ChRCCs. The mechanism for the overexpression of KIT in ChRCC is unknown. They suggested that the KIT signal pathway in ChRCCs could be activated in an auto-

**Table 2: Targets for Imatinib, Dasatinib and Nilotinib**

Target spectrum	Imatinib	Dasatinib	Nilotinib
BCR-ABL	+	+	+
PDGFR	+	+	+
c-KIT	+	+	+
Src family kinases	-	+	-
Ephrin receptor kinases	-	+	only EphB4
NQO2	+	-	+
DDR1	+	+	+
CSF-1R	-	-	+

**Table 3: Activity Sorafenib and Sunitinib in ChRCC**

Agent	No. of patients	Median PFS (months)	Partial Response No. of patients	Stable Disease No. of patients
Sunitinib	7	8.9	1	6
Sorafenib	5	27.5	2	3

crine way [19]. In summary 70 cases, based on 4 reports investigators were unable to detect activating mutations within exon 17 of the *c-kit* gene [19-22]. Absence of *c-kit* mutation could be argue for potential effectiveness of imatinib therapy in patients with metastatic ChRCCs.

### Potential targeted therapy for advanced ChRCC

Now we have three potentially active and targeted agents against CD 117: imatinib, dasatinib and nilotinib.

#### Imatinib

as KIT tyrosine kinase inhibitor (TKI) is an accepted treatment of chronic eosinophilic leukemia, hypereosinophilic syndrome, chronic myeloid leukemia, myelodysplastic/myeloproliferate syndrome, acute lymphoblastic leukemia, dermatofibrosarcoma protuberans, gastrointestinal stromal tumors [18]. The targets for imatinib include: BCR/ABL, CD 117, PDGFRA (platelet-derived growth factor receptor) [23] and also DDR1 (discoidin domain receptor 1), NQO2 (quinone reductase QR2) [24,25].

#### Dasatinib

is a second-line multikinase (besides BCR/ABL kinase) inhibitor. Dasatinib is used in patients with chronic myeloid leukemia or acute lymphoblastic leukemia with resistance or intolerance of imatinib. *In vitro*, it has approximately 325-fold greater potency than imatinib in inhibition of BCR/ABL kinase [26]. In phase II trial, dasatinib increased response rates by > 2-fold versus high-dose of imatinib. The targets for dasatinib include: BCR/ABL, CD 117, PDGFRA, DDR1, DDR2, Src family kinases and ephrin receptor kinases [24,27].

#### Nilotinib

is the result of modifications to the imatinib molecule [28,29]. Nilotinib like imatinib, inhibits BCR/ABL, CD 117, PDGFRA, NQO2, DDR1 [24,25,29]. Nilotinib also inhibits CSF-1R (colony-stimulating factor-1 receptor) [30] and EphB4 (ephrin receptor) [31]. Nilotinib was 43-60 times more potent than imatinib in cell lines (KBM5, KBM7) [32].

A phase II clinical trial confirmed activity of nilotinib in imatinib-resistant or imatinib-intolerant chronic myeloid leukemia [33] (Table 2).

We realize that this treatment hypothesis is controversial. Up to now, we have not found cases of successful treatment in the literature. But we think, that prospective trials with these agents in ChRCC should clarify their use in the future.

Other interesting therapies for advanced ChRCC may include therapies used in advanced clear cell renal carcinoma (CCRCC). Both, **sorafenib** and **sunitinib** showed clinical activity in randomized clinical trials in treatment metastatic CCRCC [34,35]. These are tyrosine kinases inhibitors including vascular endothelial growth factor receptor (VEGFR) and platelet-derived growth factor receptor (PDGFR) [36,37].

VEGF and PDGF are markers of angiogenesis which plays an essential role in tumor growth and metastatization. Overexpression VEGF and PDGF in RCCs is associated with defective von Hippel-Lindau (VHL) protein. It can induce the expression of the genes involving in angiogenesis through the hypoxia-inducible factor 1 $\alpha$  (HIF-1 $\alpha$ ) pathway. *VHL* is inactivated in up to 80% of sporadic cases of clear-cell carcinoma [38].

ChRCC can be associated with high serum levels of VEGF, making VEGF-targeted therapy an attractive therapeutic option [39].

In biochemical and cellular tests both agents inhibit CD 117. They seem to be next potential targeted therapy for advanced ChRCC [37].

Choueiri et al. confirmed, that sunitinib and sorafenib are active agents in metastatic ChRCC: 75% of patients had stable disease (SD) more than 3 months and 25% had partial response (PR) [37] Table 3.

### Conclusion

Currently, we do not have any effective treatment for the metastatic disease apart from surgical procedures. Overexpression of CD117 on cellular membranes of ChRCC could be a potential target for kinase inhibitors like: imatinib, dasatinib, nilotinib. The potential targets for other kinase inhibitors (sunitinib and sorafenib) in ChRCC seem to be VEGFR and PDGFR. In conclusion, these observations are the basis for formulating research

hypotheses which should be verified in prospective studies.

### Competing interests

The authors declare that they have no competing interests.

### Authors' contributions

RS, LB, MM participated in the sequence alignment and drafted the manuscript. BG was responsible for pathomorphology. RS, CS was responsible for coordination. All authors read and approved the final manuscript.

### Acknowledgements

Special thanks for Professor W. Kozłowski, The Head of Department of Pathomorphology, Military Institute of Health Services in Warsaw.

### References

1. Wojciechowska U, Didkowska J, Tarnowski W, Zatoński W: **Nowotwory złośliwe w Polsce w 2004 roku. Zachorowania na nowotwory złośliwe (stan na 30 czerwca 2006 roku);** Warszawa 2006:94-101.
2. Pawlicki M, Siedlecki P: **Nowotwory układu moczowo-płciowego.** In W: *Onkologia Kliniczna. Maciej Krakowski (red.)* Wydawnictwo Medyczne Borgis; Warszawa; 2006:922-925.
3. Eble JN, Sauter G, Epstein JI, Sesterhenn IA: **Tumors of The system and male genital organs.** Lyon, France: IARC Press; 2004.
4. Cheville JC, Lohse CM, Zincke H, Weaver H, Blute AL, Michael L: **Comparisons of outcome and prognostic features among histologic subtypes of renal cell carcinoma.** *Am J Surg Pathol* 2003, **27**:612-624.
5. Prasad SR, Humphrey PA, Jay R, Narra S, Sringley JR, Cortez AD, Dalrymple NC, Chintapalli KN: **Common and uncommon Histologic Subtype of Renal Cell Carcinoma: Imaging Spectrum with Pathologic Correlation.** *Radiographics* 2006, **26**:1795-1810.
6. Amin MB, Paner GP, Alvarado-Cabrero A, Alvarado-Cabrero I, Young AN, Stricker HJ, Lyles RH, Moch H: **Chromophobe Renal Cell Carcinoma: Histomorphologic Characteristics and Evaluation of Conventional Pathologic prognostic Parameters in 145 Cases.** *Am J Surg Pathol* 2008, **32**:1822-1834.
7. Beck SDW, Manish I, Patel IM, Snyder ME, Kattan MW, Motzer RJ, Reuter VE, Russo P: **Effect of Papillary and Chromophobe Cell Type on Disease-Free Survival After Nephrectomy for Renal Cell Carcinoma.** *Ann of Surg Oncol*; 2004, **11**(1):71-77.
8. Thoenes W, Storkel S, Rumpelt MJ: **Human chromophobe cell renal carcinoma.** *Virchows Arch Cell Pathol* 1985, **48**:207-217.
9. Wu SL, Fishman IJ, Shanon RL: **Chromophobe Renal Cell Carcinoma With Extensive Calcification and Ossification.** *Ann of Diag Pathol* 2002, **6**(4):244-247.
10. Skinnider BF, Flope AL, Hennigar RA, Lim SD, Cohen C, Tomboli P: **Distribution of cytokeratins and Vimentin in adult renal neoplasms and normal renal tissue.** *Am J Surg pathol* 2005, **29**:747-754.
11. Martignoni G, Pea M, Chilosi M, Brunelli M, Scarpa A, Colato C, Tardanico R, Zamboni G, Bonetti F: **Parvalbumin is constantly expressed in Chromophobe Renal Carcinoma.** *Mod Pathol* 2001, **14**(8):760-767.
12. Patard J-J, Leray E, Rioux-Leclercq N, Cindolo L, Ficarra V, Zisman A, De La Taille A, Tostain J, Artibani W, Abbou CC, Lobel B, Guillé F, Chopin DK, Mulders PFA, Wood CG, Swanson DA, Figlin RA, Belldegrun AS, Pantuck AJ: **Prognostic Value of Histologic Subtypes in Renal Cell Carcinoma: A Multicenter Experience.** *J Clin Oncol* 2005, **23**(12):2763-2771.
13. Kondo T, Nakazawa H, Sakai F, Tomo K, Shiro O, Yasunobu H, Hiroshi T: **Spoke-wheel-like enhancement as an important imaging finding of chromophobe cell renal carcinoma: carcinoma retrospective analysis on computed tomography and magnetic resonance imaging studies.** *Int Urol* 2004, **11**:817-824.
14. Cohen D, Zhou M: **Molecular genetics of familial renal cell carcinoma syndromes.** *Clin Lab Med* 2005, **25**:259-277.
15. Vira MA, Novakovic KR, Pinto PA, Linehan WM: **Genetic basis of kidney cancer: a model for developing molecular-targeted therapies.** *BJU Int* 2007, **99**:1223-1229.
16. Jones TD, Eble JN, Cheng L: **Application of molecular diagnostic techniques to renal epithelial neoplasms.** *Clin Lab Med* 2005, **25**:279-303.
17. Kovacs A, Storkel S, Thoenes W, Kovacs G: **Mitochondrial and chromosomal DNA alterations in human chromophobe renal cell carcinoma.** *J Pathol* 1992, **167**:273-277.
18. Miettinen M, Lasota J: **KIT (CD117): a review on expression in normal and neoplastic tissues, and mutations and their clinicopathologic correlation.** *Appl Immunohistochem Mol Morphol* 2005, **13**(3):205-220.
19. Yamazaki K, Sakamoto M, Ohta T, Kanai Y, Ohki M, Hirohashi S: **Overexpression of KIT in chromophobe renal cell carcinoma.** *Oncogene* 2003, **22**:847-852.
20. Zhen-Hua L, Eun Mee H, Eung Seok L, Kim Chul W, Kim Han K, Kim I, Kim Y-S: **A distinct expression pattern and point mutation of c-kit in papillary renal cell carcinomas.** *Modern Pathology* 2004, **17**:611-616.
21. Krúger S, Sotlar K, Kausch I, Horny HP: **Expression of KIT (CD 117) in renal cell carcinoma and renal oncocytoma.** 2005, **68**:269-275.
22. Pan CC, Chen CH, Chiang H: **Overexpression of KIT (CD 117) in chromophobe renal cell carcinoma and renal oncocytoma.** *Am J Clin Pathol* 2004, **121**:878-883.
23. Heinrich MC, Shoemaker JS, Corless CL, Hollis D, Demetri GD, Bertagnoli MM, Fletcher JA: **Correlation of target kinase genotype with clinical activity of imatinib mesylate in patients with metastatic GI stromal tumors (GISTs) expressing KIT (KIT+) [abstract].** *J Clin Oncol* 2005, **23**(16S):3s. Abstract 7
24. Hantschel O, Rix U, Superti-Furga G: **Target spectrum of the BCR-ABL inhibitors imatinib, nilotinib and dasatinib.** *Volume 49. Issue 4 Leukemia & Lymphoma*; 2008:615-619.
25. Rix U, Hantschel O, Durnberger G, Rensing Rix LL, Planyavsky M, Fernbach NV, Kaupe I, Bennett KL, Valent P, Colinge J, Köcher T, Superti-Furga G: **Chemical proteomic profiles of the BCR-ABL inhibitors imatinib, nilotinib, and dasatinib reveal novel kinase and nonkinase targets.** *Blood* 2007, **110**:5055-5063.
26. O'Hare J, Walters DK, Stoffregen DP, Sherbenou DW, Heinrich MC, Deininger MW, Druker BJ: **Combined Abl inhibitor therapy for minimizing drug resistance in chronic myeloid leukemia: Src/Abl inhibitors are compatible with imatinib.** *Clin Cancer Res* 2005, **11**:6987-6993.
27. Kantarjian H, Pasquini R, Hamerschlag N, Rousselot P, Holowiecki J, Jootar S, Robak T, Khoroshko N, Masszi T, Skotnicki A, Hellmann A, Zaritsky A, Golenkov A, Radich J, Hughes T, Countouriotis A, Shah N: **Dasatinib or high-dose imatinib for chronic-phase chronic myeloid leukemia after failure of first-line imatinib: a randomized phase 2 trial.** *Blood* 2007, **109**:5143-5150.
28. Wiesberg E, Manley PW, Breitenstein W, Brügger J, Cowan-Jacob SW, Ray A, Huntly B, Fabbro D, Fendrich G, Hall-Meyers E, Kung AL, Mestan J, Daley GQ, Callahan L, Catley L, Cavazza C, Mohammed A, Neuberg D, Wright RD, Gilliland DG, Griffin JD: **Characterization of AMN107, a selective inhibitor of native and mutant BCR-ABL.** *Cancer Cell* 2005, **7**(2):129-141.
29. Deininger MW: **Nilotinib.** *Clin Cancer Res* 2008, **14**(13):
30. Brownlow N, Russell AE, Saravanapavan H, Wiesmann M, Murray JM, Manley PW, Dibb NJ: **Comparison of nilotinib and imatinib inhibition of FMS receptor signaling, macrophage production and osteoclastogenesis.** *Leukemia* 2008, **22**:649-652.
31. Wiesberg E, Manley PW, Cowan-Jacob SW, Hochhaus A, Griffin JD: **Second generation inhibitors of BCR-ABL for the treatment of imatinib-resistant chronic myeloid leukaemia.** *Nature Reviews Cancer* 2007, **7**:345-356.
32. Golemovic M, Verstovsek S, Giles F, Cortes J, Manshour I, Manley PW, Mestan J, Dugan M, Alland L, Griffin JD, Arlinghaus RB, Sun T, Kantarjian H, Beran M: **AMN107, a Novel Aminopyrimidine Inhibitor of Bcr-Abl, Has In vitro Activity against Imatinib-Resistant Chronic Myeloid Leukemia.** *Cancer Res* 2005, **11**(13):4941-4947.
33. Kantarjian HM, Giles F, Gattermann N, Bhalla K, Alimena G, Palandri F, Ossenkoppele GJ, Nicolini F-E, O'Brien SG, Litzow M, Bhatia R, Cervantes F, Haque A, Shou Y, Resta DJ, Weitzman A, Hochhaus A, Phillip le Coutre: **Nilotinib (formerly AMN107), a highly selective BCR-ABL tyrosine kinase inhibitor, is effective in patients with Philadelphia chromosome-positive chronic myelogenous leukemia in chronic phase following imatinib resistance and intolerance.** *Blood* 2007, **110**(10):3540-3546.

34. Motzer RJ, Hudson TE, Tomczak P, Michaelson D, Bukowski RM, Rixe O, Oudard S, Negrier S, Szczylik C, Kim STBS, Chen I, Bycott PW, Baum CM, Figlin RA: **Sunitinib versus interferon alfa in metastatic renal cell carcinoma.** *N Eng J Med* 2007, **356**:115-124.
35. Escudier B, Eisen T, Stadler WM, Szczylik C, Oudard S, Siebels M, Negrier S, Chevreau C, Solska E, Desai AA, Rolland F, Demkow T, Hutson TEDO, Gore M, Freeman S, Schwartz B, Shan M, Simantov R, Bukowski RM: **Sorafenib in advanced renal-cell carcinoma.** *N Eng J Med* 2007, **356**:125-134.
36. Mendel DB, Laird AD, Xin X, Louie SG, Christensen JG, Li G, Schreck RE, Abrams TJ, Ngai TJ, Lee LB, Murray LJ, Carver J, Chan E, Moss KG, Haznedar JO, Sukbuntherng J, Blake RA, Sun L, Tang C, Miller T, Shirazian S, McMahon G, Cherrington JM: **In vivo antitumor activity of SU1 a novel tyrosine kinase inhibitor targeting vascular endothelial growth factor and platelet-derive d growth factor receptors: determination of a pharmacokinetic/pharmacodynamic relationship.** *Clin Cancer Res* 1248, **9**:327-37.
37. Choueiri TK, Plantade A, Elson P, Negrier S, Ravaud A, Oudard S, Zhou M, Rini BI, Bukowski RM, Escudier B: **Efficacy of Sunitinib and Sorafenib in Metastatic Papillary and Chromophobe Renal Cell Carcinoma.** *J Clin Oncol* 2008, **26**(1):127-131.
38. Motzer RJ, Bander NH, Nanus DM: **Renal-cell carcinoma.** *N Eng J Med* 1996, **335**:865-875.
39. Schips L, Dalpiaz O, Lipsky K, Langner C, Rehak P, Puerstner P, Pummer K, Zigeuner R: **Serum levels of vascular endothelial growth factor (VEGF) and endostatin in renal cell carcinoma patients compared to a control group.** *Eur Urol* 2007, **51**:168-174.

Publish with **BioMed Central** and every scientist can read your work free of charge

"BioMed Central will be the most significant development for disseminating the results of biomedical research in our lifetime."

Sir Paul Nurse, Cancer Research UK

Your research papers will be:

- available free of charge to the entire biomedical community
- peer reviewed and published immediately upon acceptance
- cited in PubMed and archived on PubMed Central
- yours — you keep the copyright

Submit your manuscript here:  
[http://www.biomedcentral.com/info/publishing\\_adv.asp](http://www.biomedcentral.com/info/publishing_adv.asp)

