INTERNATIONAL JOURNAL OF UROLOGY
International Journal of Urology (2015) doi: 10.1111/iju.13015

Review Article

Birt–Hogg–Dubé syndrome: Clinical and molecular aspects of recently identified kidney cancer syndrome

Hisashi Hasumi,[1] Masaya Baba,[2] Yukiko Hasumi,[3] Mitsuko Furuya[4] and Masahiro Yao[1]

[1]Department of Urology, Yokohama City University School of Medicine, Yokohama, Kanagawa, [2]International Research Center for Medical Sciences, Kumamoto University, Kumamoto, and Departments of [3]Ophthalmology and [4]Molecular Pathology, Yokohama City University School of Medicine, Yokohama, Kanagawa, Japan

Abbreviations & Acronyms
AMPK = adenosine monophosphate-activated protein kinase
BHD syndrome = Birt–Hogg–Dubé syndrome
FLCN = folliculin
FNIP1 = folliculin-interacting protein 1
FNIP2 = folliculin-interacting protein 2
HOCT = hybrid oncocytic/chromophobe tumors
mTOR = mammalian target of rapamycin
mTORC1 = mammalian target of rapamycin complex 1
VHL = von Hippel–Lindau

Correspondence: Hisashi Hasumi M.D., Ph.D., Department of Urology, Yokohama City University School of Medicine, 3-9 Fukuura, Yokohama, Kanagawa 236-0004, Japan. Email: hasumi@yokohama-cu.ac.jp

Received 9 September 2015; accepted 20 October 2015.

Abstract: Birt–Hogg–Dubé syndrome is an autosomal dominantly inherited disease that predisposes patients to develop fibrofolliculoma, lung cysts and bilateral multifocal renal tumors, histologically hybrid oncocytic/chromophobe tumors, chromophobe renal cell carcinoma, oncocytoma, papillary renal cell carcinoma and clear cell renal cell carcinoma. The predominant forms of Birt–Hogg–Dubé syndrome-associated renal tumors, hybrid oncocytic/chromophobe tumors and chromophobe renal cell carcinoma are typically less aggressive, and a therapeutic principle for these tumors is a surgical removal with nephron-sparing. The timing of surgery is the most critical element for postoperative renal function, which is one of the important prognostic factors for Birt–Hogg–Dubé syndrome patients. The folliculin gene (*FLCN*) that is responsible for Birt–Hogg–Dubé syndrome was isolated as a novel tumor suppressor for kidney cancer. Recent studies using murine models for FLCN, a protein encoded by the *FLCN* gene, and its two binding partners, folliculin-interacting protein 1 (FNIP1) and folliculin-interacting protein 2 (FNIP2), have uncovered important roles for FLCN, FNIP1 and FNIP2 in cell metabolism, which include AMP-activated protein kinase-mediated energy sensing, Ppargc1a-driven mitochondrial oxidative phosphorylation and mTORC1-dependent cell proliferation. Birt–Hogg–Dubé syndrome is a hereditary hamartoma syndrome, which is triggered by metabolic alterations under a functional loss of FLCN/FNIP1/FNIP2 complex, a critical regulator of kidney cell proliferation rate; a mechanistic insight into the FLCN/FNIP1/FNIP2 pathway could provide us a basis for developing new therapeutics for kidney cancer.

Key words: Birt–Hogg–Dubé syndrome, folliculin, kidney cancer, mitochondria, mTORC1.

In 1977, three Canadian physicians, Birt, Hogg and Dubé, reported kindred with skin nodules that they named fibrofolliculoma.[1] In 1999, the development of lung cysts and renal tumors in this kindred were reported, and this disorder was thereafter called BHD syndrome.[2] In 2002, *FLCN* was identified as a novel tumor suppressor gene responsible for BHD syndrome, and a genetic test of *FLCN* is used as a diagnostic tool for BHD syndrome.[3] Among the clinical triad of BHD syndrome, the management of kidney cancer is a key for the overall survival of BHD patients. Although FLCN was a totally novel protein with unknown function and no known domains at the time of discovery, recent studies using murine models have uncovered important roles for *FLCN* in cell metabolism.[4–10] In the present review article, we describe the clinical features and management of BHD syndrome, as well as the recent progress in basic research of the *FLCN* pathway, mainly focusing on animal models.

Clinical features of BHD syndrome

Fibrofolliculomas

After the age of 20 years, 82–92% of BHD patients in Western countries and 20–29% of Japanese Asian patients develop fibrofolliculomas, which are white papules on their face, neck and upper torso (Fig. 1).[2,11–13] There might be some difference of the skin tumor incidence between the races. Because fibrofolliculomas are histologically continuous with the

© 2015 The Japanese Urological Association

Fig. 1 Fibrofolliculloma observed in the face and neck of a BHD patient.

sebaceous glands and localized to sites with many sebaceous glands, such as the peri-nasal area, it is postulated that the origin of fibrofolliculomas might be sebaceous glands rather than hair follicles.[13] Although a clinical trial for a focal treatment using rapamycin was carried out based on the result that mTORC1 is activated under *FLCN* deficiency,[10] the 6-month treatments with rapamycin were not effective for 19 cases of fibrofolliculomas.[14] Rapamycin is a large molecule, and it is difficult to make an easily absorbed ointment.[15] Because topical rapamycin was effective for angiofibromas of tuberous sclerosis patients after a modification of ointment, an improvement of drug delivery might increase the efficacy of topical rapamycin treatment for BHD-associated fibrofolliculomas.[15]

Lung cysts

Pulmonary cysts are seen in 90% of BHD patients, and 24–29% of BHD patients develop recurrent pneumothorax at the average age of 36 years (Fig. 2).[16–21] The number of cysts varies from 30 to 400, the sizes of lung cysts vary from a few millimeters to 2 cm, and they are predominantly seen in lower and/or peripheral lesions of lungs.[22] The histology of BHD-associated lung cysts is distinct from that of other types of lung cysts. Cuboidal cells resembling type II pneumocytes are often observed in the innermost layers of BHD-associated lung cysts, and these cells show the activation of mTORC1 and hypoxia-inducible factor–vascular endothelial growth factor pathways.[23–26]

Renal tumor and its management

Between 16 and 34% of BHD patients develop renal tumors at the average age of 50 years (Fig. 3).[18,27–29] These tumors are bilateral multifocal with diverse histologies that include HOCT (50%), chromophobe renal cell carcinoma (34%), clear cell renal cell carcinoma (9%), oncocytoma (5%) and papillary renal cell carcinoma (2%).[30] Multifocal renal oncocytosis, composed of cells electron-microscopically filled with mitochondria and observed in the surrounding normal kidney of BHD-associated renal tumors in 50–58% of patients, is possibly a pre-cancer lesion.[8,30,31] Small papillary tufts are often observed in the peripheral of the tumor and are helpful for diagnosis of BHD-associated renal tumor.[32–34] Usually, the progression of these tumors is slow and nephron-sparing surgery is indicated for these types of tumor, although there is one case report of metastasis.[18] Kidney surveillance is recommended at 20 years-of-age.[35] For the kidney surveillance, computed tomography or magnetic resonance imaging is more suitable than ultrasonography, because computed tomography and magnetic resonance imaging detect renal masses of 15–20 mm with 100% detection rates, whereas ultrasonography can detect those masses with 58% detection rates.[36] We carry out the kidney surveillance every 3 years in the same manner as we survey kidneys of VHL hereditary kidney cancer syndrome. As recommended to the sporadic form of renal cell carcinoma, a complete removal of tumor lesions by partial or radical nephrectomy is primarily indicated for the treatment of BHD-related kidney cancer. However, as with other kidney cancer syndromes, having a risk of synchronous and metachronous multiple kidney cancers through the life time, the balance of oncological radicality and postoperative renal function is one of the most critical elements for the quality of life and overall survival of BHD patients. A partial nephrectomy rather than a radical nephrectomy is to be indicated for nephron sparing as far as possible. The size of the renal tumor at surgery is therefore one of the keys to success for minimizing the number of surgeries in a lifetime, as well as postoperative renal function. Based on our experiences, we operate on BHD-associated renal tumors when the diameter of the largest tumor reaches 2 cm, which is the same concept we use to operate on VHL-associated renal tumors. If renal tumors are

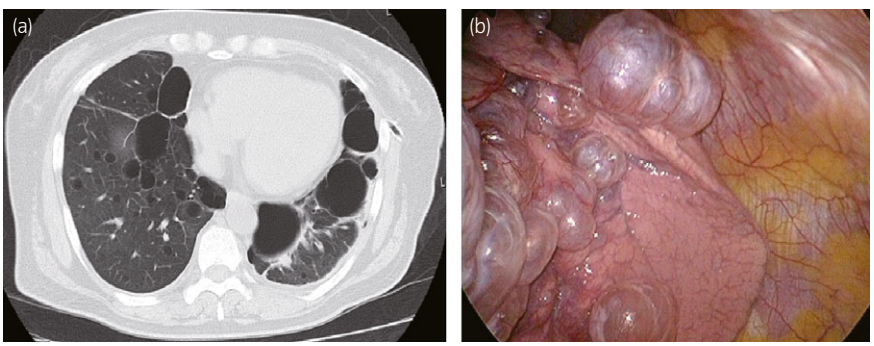

Fig. 2 Multiple lung cysts observed in BHD patients. (a) Computed tomography scan and (b) intraoperative pictures.

© 2015 The Japanese Urological Association

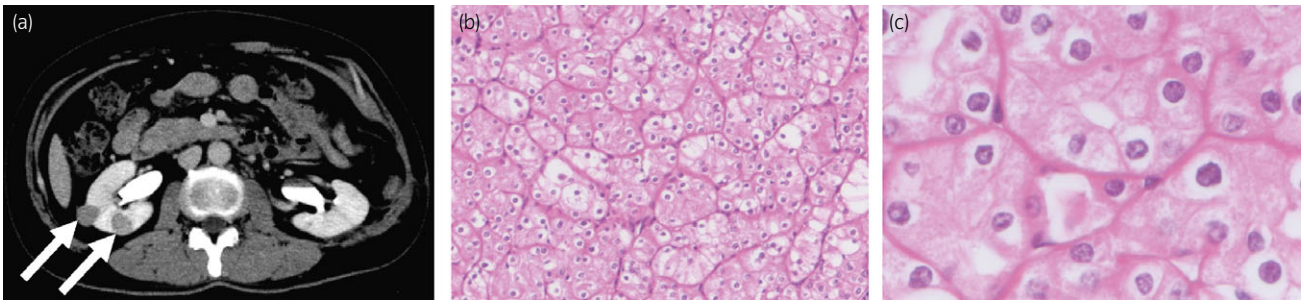

Fig. 3 (a) Computed tomography scan shows BHD-associated renal tumors (arrows). (b,c) Hematoxylin–eosin stain shows the most predominant forms of BHD-associated renal tumor, HOCT. (b) Low and (c) high magnification.

occurring bilaterally, one of the kidneys is operated on at an initial surgery. After confirmations of favorable renal function remaining, as well as of enough recovery of the patient's physical condition, we will carry out a second surgery to the other kidney. Intraoperative ultrasonography is useful for detecting impalpable buried types of tumors and small lesions undetectable with preoperative imaging studies. Intraoperative ultrasonography also clarifies the architecture of blood vessels, and the distance between tumor and urinary collecting systems. In our experience, BHD-associated renal tumors usually lack a tumor pseudocapsule, which is in contrast with VHL-associated renal tumors. In this setting, intraoperative ultrasonography serves as a useful device to define a tumor margin, which is essential for both curative resections and nephron sparing. For multifocal tumors, before resecting large or buried-type tumors, relatively small sized and palpable tumors can be removed without clamping renal vessels to minimize the renal ischemic time. The proper manual compressions onto renal parenchyma using the surgeon's fingers, which decreases a segmental blood flow, will be useful. Recent hemostatic technologies, including soft coagulation or hemostatic sponge, might be helpful to achieve a clampless surgery.[37,38] Cryoablation and radiofrequency ablation are options for the treatment of BHD-associated renal tumors, although those non-invasive treatments have disadvantages in terms of lack of pathological diagnosis and a report of large studies of these ablation therapies in BHD-associated renal tumors with long-term observation is awaited.[37] For advanced and metastatic cases, molecular targeting drugs against angiogenesis or mTOR are considered. In our limited experience, mTOR inhibitor seems to be more effective than tyrosine kinase inhibitors, as expected from the molecular mechanism of the BHD-associated renal tumors.[5,38] Immunotherapy drugs, such as interferon-α and interleukin-2, which are used for clear cell renal cell carcinoma, were not effective for BHD-associated kidney cancer.[38]

Other clinical features

It is controversial whether colon polyps and colon cancer are associated with BHD syndrome.[20,35,40] Because oncocytoma of parotid grand[27,39,41–43] and thyroid cancers have been reported in BHD patients, a cervical surveillance of BHD patients might be considered.[27,44]

FLCN, the gene responsible for BHD syndrome

Through a linkage analysis of BHD syndrome, *FLCN*, which is located on 17p11.2, was identified as the gene responsible for BHD syndrome. With highly accurate sequencing methods, the detection ratio of *FLCN* germline mutation is now approaching 90%.[3,18,27,43] To date, more than 100 types of mutations have been reported, which include insertion/deletion, nonsense/splice site mutation.[45,46] Small numbers of missense mutations have been reported, including Arg239Cys, His255Pro, Val400Ile and Lys508Arg, although a pathogenesis of these missense mutations is not well understood.[47] Insertion or deletion of a cytosine in a tract of eight cytosines in exon 11 (c.1285dupC or delC) is a mutational "hot spot" that was identified in up to 50% of BHD patients regardless of human races.[3,27,40,43,48,49] The database of folliculin sequence variations is available at the site hosted by Leiden Open Variation Database (https://grenada.lumc.nl/LOVD2/shared1/home.php?select_db=FLCN or http://www.skingenedatabase.com/variants.php?action=view_unique&select_db=FLCN).

Identification of two FLCN binding partners, FNIP1 and FNIP2

By the proteomic approach using co-immunoprecipitants pulled down by HA-tagged FLCN protein, a 130-kDa protein with unknown function was found to bind to FLCN, and this novel protein was named FNIP1.[9] The same technique was applied to HA-tagged FNIP1 protein, and FNIP1 was found to bind to AMPK, which is an important energy sensor of cells, first implying that the FLCN/FNIP1 pathway might interact with metabolic pathways.[9] Through bioinformatics analysis, a novel protein of which amino acid sequences are higly homological to those of FNIP1 was identified and named FNIP2.[6,50] The amino acid sequences of FNIP1 and FNIP2 show 49% identity and 74% similarity, indicating that FNIP1 and FNIP2 have overlapping functions.[6,50] FNIP1 and FNIP2 form a homodimer as well as a heterodimer, and bind to FLCN through the C-terminus of FLCN.[6,50] FNIP1 and FNIP2 localize predominantly in the cytoplasm, whereas FLCN localizes in both the cytoplasm and the nucleus.[6,50]

© 2015 The Japanese Urological Association

Lessons from animal models

Whole-body *Flcn* knockout mouse model

Flcn conditional knockout mouse was established by targeting exon 7 of the *Flcn* gene, and a whole-body deletion of the *Flcn* gene from both alleles was achieved using *β-actin*-Cre transgenic mouse. Homozygous whole-body *Flcn* knockout mouse was embryonically lethal from E5.5 to E6.5 with swollen vacuoles in the visceral endoderm, suggesting that *Flcn* might have important roles in phagocytosis, trafficking or digestion.[5] Heterozygous whole-body *Flcn* knockout mice, which mimic human BHD syndrome, developed kidney tumors around 1.5 years-of-age. The histology of renal tumors developed in heterozygous whole-body *Flcn* knockout mice was similar to that of human BHD-associated tumors, which includes HOCT, clear cell renal cell carcinoma and papillary renal cell carcinoma.[5,51,52] The loss of heterozygosity of the *Flcn* locus was observed in these tumors, underscoring *FLCN* as a classical tumor suppressor with the two-hit theory.[5]

Kidney-specific *Flcn* knockout mouse model

The kidney-specific *Flcn* knockout mouse model using cadherin 16 (*CDH16* or *KSP*)-Cre transgenic mouse showed enlarged polycystic kidneys, and died at 3 weeks-of-age as a result of renal failure.[10,53] In these kidneys, mTORC1 was activated, and rapamycin treatment partially decreased the size of polycystic kidneys and prolonged the survival term.[10] Mitochondrial biogenesis was increased in these kidneys and inactivation of *Ppargc1a* (peroxisome proliferator-activated receptor gamma coactivator 1 alpha), which is a co-activator for mitochondrial gene transcriptions, partially decreased the size of *Flcn*-deficient kidneys, underscoring *Ppargc1a* as a key enhancer for aberrant kidney cell proliferations under *Flcn* deficiency.[8]

Muscle-specific *Flcn* knockout mouse model

Elucidation of *Flcn* roles in metabolic organs, such as skeletal and cardiac muscle, gave us conclusive evidence that the *Flcn* pathway is associated with metabolism. The muscle-specific *Flcn* knockout mouse model using creatine kinase, muscle (*CKM*)-Cre transgenic mouse showed red-colored muscle in which mitochondrial oxidative metabolism was upregulated, as well as cardiac hypertrophy in which mTORC1 and its downstream signaling molecules were activated. The muscle color and upregulated mitochondrial biogenesis of muscle-specific *Flcn* knockout mouse was completely reversed and cardiac hypertrophy was partially ameliorated by inactivation of *Ppargc1a.*[4,8]

Whole-body *Fnip1* and/or *Fnip2* knockout mouse models

The *Fnip1* knockout mouse showed a B cell developmental defect,[54,55] red-colored muscle and cardiac hypertrophy,[7,56] suggesting that *Flcn* and *Fnip1* function co-operatively, and the deficiency of *Flcn* and *Fnip1* might phenocopy each other. However, *Fnip1* knockout mouse developed no impressive phenotype in the kidney.[7] Therefore, the *Fnip2* knockout mouse model was established; however, the *Fnip2* knockout mouse did not show any phenotype, and survived until 3 years-of-age without any health problems.[7] The homozygous whole-body *Fnip1/Fnip2* double knockout mouse was embryonically lethal, whereas both of the whole-body heterozygous *Fnip1*/homozygous *Fnip2* knockout mouse model and the whole-body homozygous *Fnip1*/heterozygous *Fnip2* knockout mouse model are not embryonically lethal, suggesting that the complete loss of both *Fnip1* and *Fnip2* might mimic *Flcn* deficiency, and one allele of either *Fnip1* or *Fnip2* is sufficient to maintain *Fnip* function.[7] The whole-body heterozygous *Fnip1*/homozygous *Fnip2* knockout mouse model developed renal tumors at approximately 1.5 years-of-age, which was similar to those developed in whole-body heterozygous *Flcn* knockout mouse model and human BHD syndrome, suggesting that interaction between Flcn and Fnip1/Fnip2 is a key element for tumor suppression.[7]

Kidney-specific *Fnip1/Fnip2* double knockout mouse model

Fnip1/Fnip2 doubly inactivated kidneys showed enlarged polycystic kidneys, which were similar to *Flcn*-deficient kidneys.[7] Kidney-specific *Fnip1/Fnip2* knockout mouse died at approximately 3 weeks-of-age, and *Fnip1/Fnip2* doubly inactivated kidneys showed an activated mTORC1 signaling pathway and upregulated mitochondrial oxidative metabolism. Inactivation of *Flcn* in *Fnip1/Fnip2* doubly inactivated kidneys did not cause any additional effect, supporting that *Fnip1/Fnip2* doubly inactivated kidneys are totally identical to *Flcn* inactivated kidneys.[7] Absolute *Fnip2* mRNA copy number was low relative to *Fnip1* in organs that showed phenotypes under *Fnip1* deficiency, but was comparable with *Fnip1* mRNA copy number in mouse kidney, suggesting that *Fnip1/Fnip2* mRNA copy number ratio might be a determinant for the phenotypes of *Fnip1* or *Fnip2* knockout mouse model.[7]

Lung-specific *Flcn* knockout mouse model

The lung epithelial cell-specific *Flcn* knockout mouse model using the *SP-C-rtTA/tetO*-Cre transgenic mouse showed the apoptosis of lung epithelial cells, alveolar enlargement, and an impairment of both epithelial barrier and overall lung function.[57] *Flcn*-null lung epithelial cells showed decreased AMPK activity and a forced activation of AMPK using 5-aminoimidazole-4-carboxamide ribonucleotide reversed the enlarged alveolar size and the impaired lung function.[57] Whole-body heterozygous *Flcn* knockout mouse showed a trend toward increased elastance after mechanical ventilation.[58] These mouse models are useful tools to clarify the mechanism of human BHD-associated lung cysts development.

© 2015 The Japanese Urological Association

Skin-specific *Flcn* knockout mouse model

Skin-specific Flcn knockout mouse model using keratin 14 (*K14*)-Cre transgenic mouse showed delays in eyelid opening, wavy fur, hair loss and epidermal hyperplasia with increased levels of mTORC1 activity.[59] p0071 (plakophilin-4), which regulates RhoA signaling, was identified as a Flcn binding partner, and loss of Flcn/p0071 function drives increased cell–cell adhesion, altered cell polarity and dysregulation of RhoA signaling.[59,60]

Other *in vivo* models

The Nihon rat model, which develops preneoplastic lesions at 3 weeks-of-age and adenoma at 8 weeks-of-age, harbors a single nucleotide insertion within exon 3 of *FLCN* (c.462_463insC), producing a frameshift and premature stop codon within the gene. Renal tumors that develop in the Nihon rat are largely composed of clear cell renal cell carcinoma and loss of heterozygosity of the *FLCN* gene was observed in these tumors.[61–63] A German shepherd harboring a H255R mutation in the *FLCN* gene develops renal cystadenocarcinoma and nodular dermatofibrosis. Renal tumors are bilateral multifocal and loss of heterozygosity at the *FLCN* locus was observed.[64–67] Drosophila testis in which *DBHD*, a drosophila homolgue of *FLCN*, was artificially deleted, showed overproliferations of germ cells, suggesting that *DBHD* might be critical for stem cell maintainance.[68]

Conclusions

BHD syndrome is an autosomal dominant hamartoma syndrome characterized by the development of renal tumors, fibrofolliculomas and lung cysts. The management of kindey cancer is important, and postoperative renal function as well as oncological radicality by surgery is critical for overall survival of BHD patients. A causative gene, *FLCN* and its interacting partners, *FNIP1* and *FNIP2*, cooperatively play important roles in metabolic pathways including AMPK-mediated energy sensing, mTORC1-dependent cell proliferations and *Ppargc1a*-driven mitochondrial oxidation; the dysregulaton of these metabolic pathways triggers aberrant kidney cell proliferations and renal tumorigenesis (Fig. 4). Deciphering how metabolic conversions under the functional loss of FLCN/FNIP1/FNIP2 complex trigger renal tuomorige-

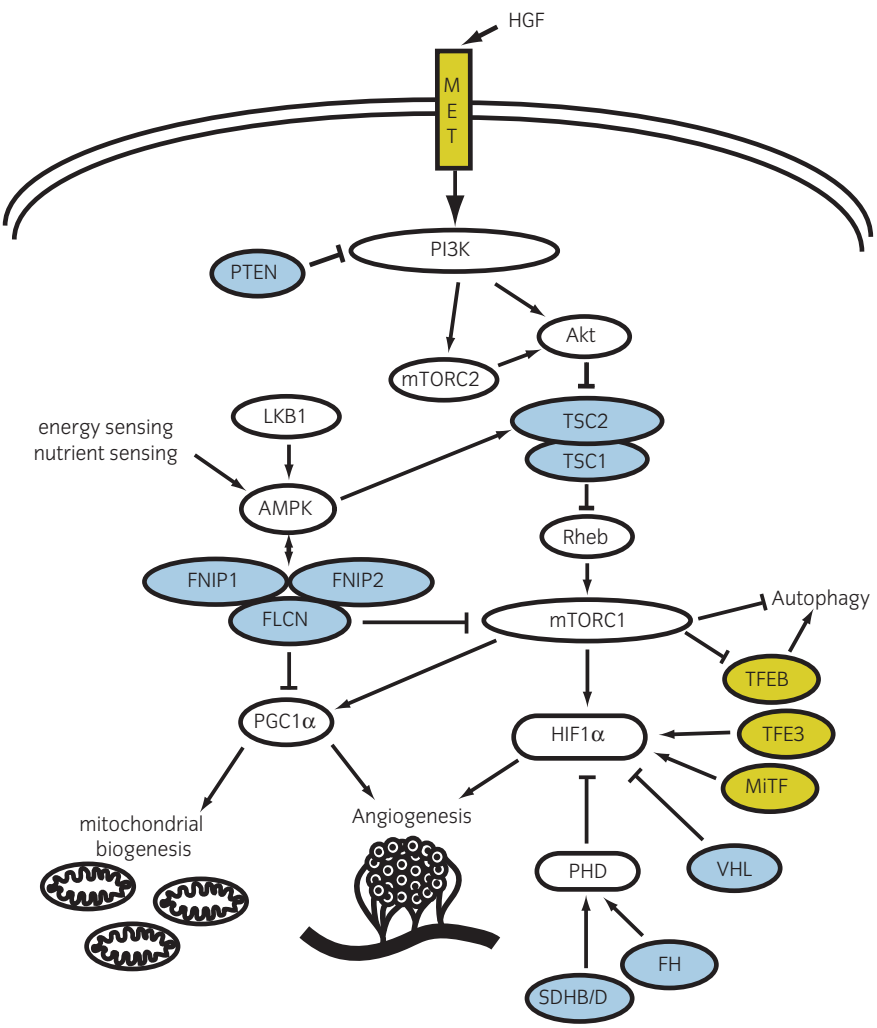

Fig. 4 Schemes of the FLCN/FNIP1/FNIP2 pathway. Yellow and light blue show oncogene and tumor suppressors for kidney cancer, respectively.

© 2015 The Japanese Urological Association

nesis might lead to the development of targeted therapeutics for kidney cancer patients.

Links for BHD research

The sites, BHD foundation (http://www.bhdsyndrome.org/) and BHD net (http://www.bhd-net.jp/) (currently Japanese only) provide useful information for BHD research.

Conflict of interest

None declared.

References

1 Birt AR, Hogg GR, Dube WJ. Hereditary multiple fibrofolliculomas with trichodiscomas and acrochordons. *Arch. Dermatol.* 1977; **113**: 1674–7.

2 Toro JR, Glenn G, Duray P *et al.* Birt-Hogg-Dube syndrome: a novel marker of kidney neoplasia. *Arch. Dermatol.* 1999; **135**: 1195–202.

3 Nickerson ML, Warren MB, Toro JR *et al.* Mutations in a novel gene lead to kidney tumors, lung wall defects, and benign tumors of the hair follicle in patients with the Birt-Hogg-Dube syndrome. *Cancer Cell* 2002; **2**: 157–64.

4 Hasumi Y, Baba M, Hasumi H *et al.* Folliculin (Flcn) inactivation leads to murine cardiac hypertrophy through mTORC1 deregulation. *Hum. Mol. Genet.* 2014; **23**: 5706–19.

5 Hasumi Y, Baba M, Ajima R *et al.* Homozygous loss of BHD causes early embryonic lethality and kidney tumor development with activation of mTORC1 and mTORC2. *Proc. Natl Acad. Sci. USA* 2009; **106**: 18722–7.

6 Hasumi H, Baba M, Hong SB *et al.* Identification and characterization of a novel folliculin-interacting protein FNIP2. *Gene* 2008; **415**: 60–7.

7 Hasumi H, Baba M, Hasumi Y *et al.* Folliculin-interacting proteins Fnip1 and Fnip2 play critical roles in kidney tumor suppression in cooperation with Flcn. *Proc. Natl Acad. Sci. USA* 2015; **112**: E1624–31.

8 Hasumi H, Baba M, Hasumi Y *et al.* Regulation of mitochondrial oxidative metabolism by tumor suppressor FLCN. *J. Natl Cancer Inst.* 2012; **104**: 1750–64.

9 Baba M, Hong SB, Sharma N *et al.* Folliculin encoded by the BHD gene interacts with a binding protein, FNIP1, and AMPK, and is involved in AMPK and mTOR signaling. *Proc. Natl Acad. Sci. USA* 2006; **103**: 15552–7.

10 Baba M, Furihata M, Hong SB *et al.* Kidney-targeted Birt-Hogg-Dube gene inactivation in a mouse model: Erk1/2 and Akt-mTOR activation, cell hyperproliferation, and polycystic kidneys. *J. Natl Cancer Inst.* 2008; **100**: 140–54.

11 Murakami Y, Wataya-Kaneda M, Tanaka M *et al.* Two Japanese cases of birt-hogg-dube syndrome with pulmonary cysts, fibrofolliculomas, and renal cell carcinomas. *Case Rep. Dermatol.* 2014; **6**: 20–8.

12 Menko FH, van Steensel MA, Giraud S *et al.* Birt-Hogg-Dube syndrome: diagnosis and management. *Lancet Oncol.* 2009; **10**: 1199–206.

13 Vernooij M, Claessens T, Luijten M, van Steensel MA, Coull BJ. Birt-Hogg-Dube syndrome and the skin. *Fam. Cancer* 2013; **12**: 381–5.

14 Gijezen LM, Vernooij M, Martens H *et al.* Topical rapamycin as a treatment for fibrofolliculomas in Birt-Hogg-Dube syndrome: a double-blind placebo-controlled randomized split-face trial. *PLoS ONE* 2014; **9**: e99071.

15 Wataya-Kaneda M, Tanaka M, Nakamura A, Matsumoto S, Katayama I. A topical combination of rapamycin and tacrolimus for the treatment of angiofibroma due to tuberous sclerosis complex (TSC): a pilot study of nine Japanese patients with TSC of different disease severity. *Br. J. Dermatol.* 2011; **165**: 912–6.

16 Tobino K, Hirai T, Johkoh T *et al.* Differentiation between Birt-Hogg-Dube syndrome and lymphangioleiomyomatosis: quantitative analysis of pulmonary cysts on computed tomography of the chest in 66 females. *Eur. J. Radiol.* 2012; **81**: 1340–6.

17 Predina JD, Kotloff RM, Miller WT, Singhal S. Recurrent spontaneous pneumothorax in a patient with Birt-Hogg-Dube syndrome. *Eur. J. Cardiothorac. Surg.* 2011; **39**: 404–6.

18 Houweling AC, Gijezen LM, Jonker MA *et al.* Renal cancer and pneumothorax risk in Birt-Hogg-Dube syndrome; an analysis of 115 FLCN mutation carriers from 35 BHD families. *Br. J. Cancer* 2011; **105**: 1912–9.

19 Toro JR, Pautler SE, Stewart L *et al.* Lung cysts, spontaneous pneumothorax, and genetic associations in 89 families with Birt-Hogg-Dube syndrome. *Am. J. Respir. Crit. Care Med.* 2007; **175**: 1044–53.

20 Zbar B, Alvord WG, Glenn G *et al.* Risk of renal and colonic neoplasms and spontaneous pneumothorax in the Birt-Hogg-Dube syndrome. *Cancer Epidemiol. Biomarkers Prev.* 2002; **11**: 393–400.

21 Kumasaka T, Hayashi T, Mitani K *et al.* Characterization of pulmonary cysts in Birt-Hogg-Dube syndrome: histopathological and morphometric analysis of 229 pulmonary cysts from 50 unrelated patients. *Histopathology* 2014; **65**: 100–10.

22 Tobino K, Gunji Y, Kurihara M *et al.* Characteristics of pulmonary cysts in Birt-Hogg-Dube syndrome: thin-section CT findings of the chest in 12 patients. *Eur. J. Radiol.* 2011; **77**: 403–9.

23 Furuya M, Tanaka R, Koga S *et al.* Pulmonary cysts of Birt-Hogg-Dube syndrome: a clinicopathologic and immunohistochemical study of 9 families. *Am. J. Surg. Pathol.* 2012; **36**: 589–600.

24 Nishii T, Tanabe M, Tanaka R *et al.* Unique mutation, accelerated mTOR signaling and angiogenesis in the pulmonary cysts of Birt-Hogg-Dube syndrome. *Pathol. Int.* 2013; **63**: 45–55.

25 Furuya M, Nakatani Y. Birt-Hogg-Dube syndrome: clinicopathological features of the lung. *J. Clin. Pathol.* 2013; **66**: 178–86.

26 Koga S, Furuya M, Takahashi Y *et al.* Lung cysts in Birt-Hogg-Dube syndrome: histopathological characteristics and aberrant sequence repeats. *Pathol. Int.* 2009; **59**: 720–8.

27 Toro JR, Wei MH, Glenn GM *et al.* BHD mutations, clinical and molecular genetic investigations of Birt-Hogg-Dube syndrome: a new series of 50 families and a review of published reports. *J. Med. Genet.* 2008; **45**: 321–31.

28 Pavlovich CP, Grubb RL 3rd, Hurley K *et al.* Evaluation and management of renal tumors in the Birt-Hogg-Dube syndrome. *J. Urol.* 2005; **173**: 1482–6.

29 Benusiglio PR, Giraud S, Deveaux S *et al.* Renal cell tumour characteristics in patients with the Birt-Hogg-Dube cancer susceptibility syndrome: a retrospective, multicentre study. *Orphanet J. Rare Dis.* 2014; **9**: 163.

30 Pavlovich CP, Walther MM, Eyler RA *et al.* Renal tumors in the Birt-Hogg-Dube syndrome. *Am. J. Surg. Pathol.* 2002; **26**: 1542–52.

31 Nagashima Y, Mitsuya T, Shioi KI *et al.* Renal oncocytosis. *Pathol. Int.* 2005; **55**: 210–5.

32 Kuroda N, Furuya M, Nagashima Y *et al.* Review of renal tumors associated with Birt-Hogg-Dube syndrome with focus on clinical and pathobiological aspects. *Pol. J. Pathol.* 2014; **65**: 93–9.

33 Kuroda N, Furuya M, Nagashima Y *et al.* Intratumoral peripheral small papillary tufts: a diagnostic clue of renal tumors associated with Birt-Hogg-Dube syndrome. *Ann. Diagn. Pathol.* 2014; **18**: 171–6.

34 Kuroda N, Tanaka A, Ohe C *et al.* Review of renal oncocytosis (multiple oncocytic lesions) with focus on clinical and pathobiological aspects. *Histol. Histopathol.* 2012; **27**: 1407–12.

35 Khoo SK, Giraud S, Kahnoski K *et al.* Clinical and genetic studies of Birt-Hogg-Dube syndrome. *J. Med. Genet.* 2002; **39**: 906–12.

36 Jamis-Dow CA, Choyke PL, Jennings SB, Linehan WM, Thakore KN, Walther MM. Small (< or = 3-cm) renal masses: detection with CT versus US and pathologic correlation. *Radiology* 1996; **198**: 785–8.

37 Stamatakis L, Metwalli AR, Middelton LA. Marston Linehan W. Diagnosis and management of BHD-associated kidney cancer. *Fam. Cancer* 2013; **12**: 397–402.

38 Nakamura M, Yao M, Sano F *et al.* A case of metastatic renal cell carcinoma associated with Birt-Hogg-Dube syndrome treated with molecular-targeting agents. *Hinyokika Kiyo* 2013; **59**: 503–6.

39 Pradella LM, Lang M, Kurelac I *et al.* Where Birt-Hogg-Dube meets Cowden syndrome: mirrored genetic defects in two cases of syndromic oncocytic tumours. *Eur. J. Hum. Genet.* 2013; **21**: 1169–72.

40 Nahorski MS, Lim DH, Martin L *et al.* Investigation of the Birt-Hogg-Dube tumour suppressor gene (FLCN) in familial and sporadic colorectal cancer. *J. Med. Genet.* 2010; **47**: 385–90.

41 Maffe A, Toschi B, Circo G *et al.* Constitutional FLCN mutations in patients with suspected Birt-Hogg-Dube syndrome ascertained for non-cutaneous manifestations. *Clin. Genet.* 2011; **79**: 345–54.

42 Liu V, Kwan T, Page EH. Parotid oncocytoma in the Birt-Hogg-Dube syndrome. *J. Am. Acad. Dermatol.* 2000; **43**: 1120–2.

43 Schmidt LS, Nickerson ML, Warren MB *et al.* Germline BHD-mutation spectrum and phenotype analysis of a large cohort of families with Birt-Hogg-Dube syndrome. *Am. J. Hum. Genet.* 2005; **76**: 1023–33.

© 2015 The Japanese Urological Association

44 Kluger N, Giraud S, Coupier I *et al.* Birt-Hogg-Dube syndrome: clinical and genetic studies of 10 French families. *Br. J. Dermatol.* 2010; **162**: 527–37.

45 Lim DH, Rehal PK, Nahorski MS *et al.* A new locus-specific database (LSDB) for mutations in the folliculin (FLCN) gene. *Hum. Mutat.* 2010; **31**: E1043–51.

46 Benhammou JN, Vocke CD, Santani A *et al.* Identification of intragenic deletions and duplication in the FLCN gene in Birt-Hogg-Dube syndrome. *Genes Chromosom. Cancer* 2011; **50**: 466–77.

47 Nahorski MS, Reiman A, Lim DH *et al.* Birt Hogg-Dube syndrome-associated FLCN mutations disrupt protein stability. *Hum. Mutat.* 2011; **32**: 921–9.

48 Khoo SK, Bradley M, Wong FK, Hedblad MA, Nordenskjold M, Teh BT. Birt-Hogg-Dube syndrome: mapping of a novel hereditary neoplasia gene to chromosome 17p12-q11.2. *Oncogene* 2001; **20**: 5239–42.

49 Leter EM, Koopmans AK, Gille JJ *et al.* Birt-Hogg-Dube syndrome: clinical and genetic studies of 20 families. *J. Invest. Dermatol.* 2008; **128**: 45–9.

50 Takagi Y, Kobayashi T, Shiono M *et al.* Interaction of folliculin (Birt-Hogg-Dube gene product) with a novel Fnip1-like (FnipL/Fnip2) protein. *Oncogene* 2008; **27**: 5339–47.

51 Hudon V, Sabourin S, Dydensborg AB *et al.* Renal tumour suppressor function of the Birt-Hogg-Dube syndrome gene product folliculin. *J. Med. Genet.* 2010; **47**: 182–9.

52 Hartman TR, Nicolas E, Klein-Szanto A *et al.* The role of the Birt-Hogg-Dube protein in mTOR activation and renal tumorigenesis. *Oncogene* 2009; **28**: 1594–604.

53 Chen J, Futami K, Petillo D *et al.* Deficiency of FLCN in mouse kidney led to development of polycystic kidneys and renal neoplasia. *PLoS ONE* 2008; **3**: e3581.

54 Park H, Staehling K, Tsang M *et al.* Disruption of Fnip1 reveals a metabolic checkpoint controlling B lymphocyte development. *Immunity* 2012; **36**: 769–81.

55 Baba M, Keller JR, Sun HW *et al.* The folliculin-FNIP1 pathway deleted in human Birt-Hogg-Dube syndrome is required for murine B-cell development. *Blood* 2012; **120**: 1254–61.

56 Reyes NL, Banks GB, Tsang M *et al.* Fnip1 regulates skeletal muscle fiber type specification, fatigue resistance, and susceptibility to muscular dystrophy. *Proc. Natl Acad. Sci. USA* 2015; **112**: 424–9.

57 Goncharova EA, Goncharov DA, James ML *et al.* Folliculin controls lung alveolar enlargement and epithelial cell survival through E-cadherin, LKB1, and AMPK. *Cell Rep.* 2014; **7**: 412–23.

58 Khabibullin D, Medvetz DA, Pinilla M *et al.* Folliculin regulates cell-cell adhesion, AMPK, and mTORC1 in a cell-type-specific manner in lung-derived cells. *Physiol. Rep.* 2014; **2**: e12107.

59 Medvetz DA, Khabibullin D, Hariharan V *et al.* Folliculin, the product of the Birt-Hogg-Dube tumor suppressor gene, interacts with the adherens junction protein p0071 to regulate cell-cell adhesion. *PLoS ONE* 2012; **7**: e47842.

60 Nahorski MS, Seabra L, Straatman-Iwanowska A *et al.* Folliculin interacts with p0071 (plakophilin-4) and deficiency is associated with disordered RhoA signalling, epithelial polarization and cytokinesis. *Hum. Mol. Genet.* 2012; **21**: 5268–79.

61 Togashi Y, Kobayashi T, Momose S, Ueda M, Okimoto K, Hino O. Transgenic rescue from embryonic lethality and renal carcinogenesis in the Nihon rat model by introduction of a wild-type Bhd gene. *Oncogene* 2006; **25**: 2885–9.

62 Okimoto K, Sakurai J, Kobayashi T *et al.* A germ-line insertion in the Birt-Hogg-Dube (BHD) gene gives rise to the Nihon rat model of inherited renal cancer. *Proc. Natl Acad. Sci. USA* 2004; **101**: 2023–7.

63 Kouchi M, Okimoto K, Matsumoto I, Tanaka K, Yasuba M, Hino O. Natural history of the Nihon (Bhd gene mutant) rat, a novel model for human Birt-Hogg-Dube syndrome. *Virchows Arch.* 2006; **448**: 463–71.

64 Lingaas F, Comstock KE, Kirkness EF *et al.* A mutation in the canine BHD gene is associated with hereditary multifocal renal cystadenocarcinoma and nodular dermatofibrosis in the German Shepherd dog. *Hum. Mol. Genet.* 2003; **12**: 3043–53.

65 Lium B, Moe L. Hereditary multifocal renal cystadenocarcinomas and nodular dermatofibrosis in the German shepherd dog: macroscopic and histopathologic changes. *Vet. Pathol.* 1985; **22**: 447–55.

66 Bonsdorff TB, Jansen JH, Thomassen RF, Lingaas F. Loss of heterozygosity at the FLCN locus in early renal cystic lesions in dogs with renal cystadenocarcinoma and nodular dermatofibrosis. *Mamm. Genome* 2009; **20**: 315–20.

67 Bonsdorff TB, Jansen JH, Lingaas F. Second hits in the FLCN gene in a hereditary renal cancer syndrome in dogs. *Mamm. Genome* 2008; **19**: 121–6.

68 Singh SR, Zhen W, Zheng Z *et al.* The Drosophila homolog of the human tumor suppressor gene BHD interacts with the JAK-STAT and Dpp signaling pathways in regulating male germline stem cell maintenance. *Oncogene* 2006; **25**: 5933–41.

© 2015 The Japanese Urological Association